Clinical Expert Series

Precancerous Squamous Lesions of the Vulva

Kathryn C. Welch, MD, Hope K. Haefner, MD, and Natalie A. Saunders, MD

The rate of vulvar cancer rates is rising, with high-grade squamous intraepithelial lesions, also known as vulvar intraepithelial neoplasia, and differentiated vulvar intraepithelial neoplasia representing key premalignant precursors to vulvar squamous cell carcinoma. Recent advances in classification and understanding of its causes—both human papillomavirus (HPV) associated and HPV independent—have significant implications for the diagnosis and management of these conditions. This review summarizes the evolving terminology, pathogenesis, clinical presentation, and current treatment strategies for vulvar squamous precancers, emphasizing the importance of distinguishing between the two major precancer subtypes to guide appropriate care.

(Obstet Gynecol 2026;148:183–93)

DOI: 10.1097/AOG.0000000000006150

Vulvar precancers are stratified into human papillomavirus (HPV)–associated and HPV-independent subtypes.[1] Both subtypes can be associated with vulvar squamous cell carcinomas. The HPV-dependent vulvar squamous cell carcinomas are the most common form of vulvar cancer. Overall, the distinction between HPV-associated and HPV-independent vulvar cancers and their precursor lesions is crucial for understanding pathogenesis, epidemiology, and potential prevention strategies.[2]

Although vulvar cancer represents only 5–8% of gynecologic cancers in the United States, the rate of vulvar cancer is rising.[3] HPV-associated lesions of the female genitalia have been well described; however, the incidence has risen over recent decades, resulting in increased interest in these conditions. Diagnosis relies on clinical suspicion, visual inspection, and histopathologic confirmation. Unlike cervical lesions, no effective screening strategies exist for precancerous vulvar lesions. The American College of Obstetricians & Gynecologists recommends treatment of all patients with vulvar high-grade squamous intraepithelial lesions (HSILs).[4] Early recognition and appropriate management are critical, particularly in light of the diverse behavior of the subtypes, with some progressing rapidly to malignancy and others persisting indolently. Understanding the nuances of these conditions is therefore essential in optimizing patient care.

CLASSIFICATION OF VULVAR PRECANCERS

As our understanding of HPV and vulvar dermatoses has increased, the complexity of classification systems has evolved.[5] In the current state, multiple classification systems are used, and experts acknowledge the confusion this creates.

Before the development of any classification system, precancerous lesions of the vulva were referred to as Bowen disease, similar to other cutaneous skin lesions. The original classification system of precancerous vulvar conditions was reported in 1986 by the terminology committee of the International Society for the Study of Vulvovaginal Disease (ISSVD).[6,7] Vulvar intraepithelial neoplasia (VIN) was graded as VIN 1 (mild dysplasia) or VIN 2–3 (severe dysplasia or carcinoma in situ). This language is still used in some form today, but in practice, it has confused clinicians on the cancer progression risk for VIN 1.[5] Nearly 2 decades later, the World Health Organization (WHO) also aligned the language to three subtypes. In 2004, the ISSVD updated the terminology into a two-tiered system distinguishing between HPV-related and non–HPV-related lesions and highlighted that VIN 1 was not a significant

From the University of Michigan, Ann Arbor, Michigan.

Each author has confirmed compliance with the journal's requirements for authorship.

Corresponding author: Kathryn Welch, MD, University of Michigan, Ann Arbor, MI; kacwelch@med.umich.edu.

Financial Disclosure

Hope Haefner, MD, is a past author on UpToDate. The other authors did not report any potential conflicts of interest.

© 2025 by the American College of Obstetricians & Gynecologists. Published by Wolters Kluwer Health, Inc. All rights reserved.

ISSN: 0029-7844/26

© 2025 by the American College of Obstetricians & Gynecologists. Published by Wolters Kluwer Health, Inc. Unauthorized reproduction of this article is prohibited.

precursor to vulvar squamous cell carcinoma.[5] The lower anogenital squamous terminology criteria, developed in 2012, were a robust collaboration focusing mainly on HPV-related verbiage.[8] The 2015 ISSVD revision introduced a multidisciplinary-driven two-tiered system of usual-type VIN and differentiated VIN.[5,9] Furthermore, in 2020, the WHO completed the classification of female genital tumors on the basis of the morphology of the pathology review. A two-tiered system was also used in this terminology, classifying usual-type VIN as HPV associated and differentiated VIN as HPV independent.[10] Table 1 illustrates the evolving terminology. We use the current WHO classification in this review to discuss overarching commonalities of precancerous lesions of the vulva and HPV associated and HPV independent to discuss the two pathways.

ETIOLOGY, PATHOGENESIS, AND RISK FACTORS

Human Papillomavirus and Human Papillomavirus–Associated Lesions

Human papillomavirus is the prominent pathogenetic factor in the development of low-grade squamous intraepithelial lesions (LSILs) and HSILs, as well as vulvar squamous cell carcinoma. Human papillomavirus infects basal epithelial cells. The global incidence of HPV-associated HSIL of the vulva has steadily risen, paralleling increased HPV transmission and expanded cervical surveillance programs. Human papillomavirus–associated HSIL affects predominantly premenopausal patients, although it can present in any age group. Risk factors include exposure to high-risk HPV16 and 18 genotypes, among other high-risk genotypes (HPV31, HPV33, HPV45, HPV52, and HPV58).[11] Human papillomavirus 16 appears to be the most insidious in regard to progression from HSIL to vulvar squamous cell carcinoma.[11] The viral oncoproteins E6 and E7 disrupt normal cell cycle control by inactivating the tumor suppressor proteins p53 and retinoblastoma protein, respectively, thereby promoting the development of epithelial changes.[12]

More than 80% of individuals will be exposed to HPV over their lifetimes, but the majority clear the virus. For those who carry persistent HPV, some risk factors such as tobacco use and immunosuppression are known; however, there is a gap in the literature because many patients present with persistent HPV without a known cause.[13] The natural history of HSIL progression to vulvar squamous cell carcinoma is indolent, but the actual time course is unknown and variable depending on risk factors.[9,14]

Human papillomavirus is well known to be associated with cervical dysplasia but has implications for the entirety of the lower genital tract, including the

Table 1. Evolution of Vulvar Precancerous Lesions Terminology

ISSVD 1986	ISSVD	LAST 2012	ISSVD 2015	WHO 2020
VIN 1 (mild dysplasia)	Condyloma	LSIL	LSIL of the vulva (condyloma, flat, HPV effect)	HPV-associated LSIL or VIN 1
VIN 2 (moderate dysplasia) VIN 3 (severe dysplasia) VIN 3 (carcinoma in situ)	VIN, usual type VIN, warty type VIN, basaloid type VIN, mixed type	HSIL	HSIL (vulvar HSIL, VIN usual type)	HPV-associated HSIL or VIN 2 or 3
Differentiated VIN	VIN differentiated	NA	Differentiated VIN	HPV-independent morphologic variants Differentiated VIN Differentiated exophytic vulvar intraepithelial lesion Vulvar acanthosis with altered differentiated Vulvar aberrant maturation (precursor lesion)

ISSVD, International Society for the Study of Vulvovaginal Disease; LAST, lower anogenital squamous terminology; WHO, World Health Organization; VIN, vulvar intraepithelial neoplasia; LSIL, low-grade squamous intraepithelial lesion; HPV, human papillomavirus; HSIL, high-grade squamous intraepithelial lesion; NA, not applicable.

© 2025 by the American College of Obstetricians & Gynecologists. Published by Wolters Kluwer Health, Inc. Unauthorized reproduction of this article is prohibited.

anus. Multizonal HPV-associated lesions occur together or in sequential occurrence at two or more anatomic sites: typically the cervix, vagina, vulva, and anus.[15,16] Furthermore, risk factors for multizonal HPV-associated lesions include a history of malignancy outside the lower genital tract, either HPV-mediated oropharyngeal cancer or an extragenital cancer that dampens the immune system and persistent carriage of multiple concomitant HPV infections.[15,17] Persistent high-risk HPV infection at multiple anatomic sites is uncommon but can be seen, especially in individuals with immunocompromise or those with other risk factors.[16,18,19] There appears to be a reproducible course of HPV-concomitant carriage initiating with cervical involvement and then vaginal, vulvar, and anal precancerous or cancer lesions over the course of almost 15 years.[12] Anal cancer is rare in the general population (1–2/100,000 person-years). However, patients with vulvar HSIL have the third-highest incidence ratio of anal cancer (48/100,000 person years), similar to women who are more than 10 years post solid-organ transplant. Incidence of anal cancer remains highest in men who have sex with men, aged 30 years or older with human immunodeficiency virus (HIV) infection.[20,21] With this in mind, multizonal testing is discussed in the paragraph on surveillance.

Low-grade squamous intraepithelial lesions and VIN 1 are also known as genital warts or condyloma acuminatum. These occur from exposure to low-risk HPV strains, most commonly the 6 and 11 genotypes.[22] These often present as flesh-colored lesions but can be highly morphologically variable. Low-grade squamous intraepithelial lesions do not progress to HSIL or vulvar squamous cell carcinoma, but patients can present with both LSIL and HSIL concurrently.

Human Papillomavirus–Independent Lesions

Vulvar lichen sclerosus, most often associated with acquiring HPV-independent lesions, especially differentiated VIN, is the primary condition linked to HPV-independent lesions compared with other underlying dermatoses. Lichen sclerosus carries a 3.5–7% lifetime risk of vulvar squamous cell carcinoma.[23] There is a paucity of data, but it is likely that recalcitrant vulvar lichen sclerosus places patients at a higher risk for precancerous lesions and vulvar squamous cell carcinoma. Differentiated VIN poses a higher risk to progression to vulvar squamous cell carcinoma than HPV-associated VIN. Small cohorts of HPV-independent differentiated VIN are reported in lichen simplex chronicus and lichen planus. However, it is difficult to determine whether there is coexisting lichen sclerosus, misdiagnosis, or HPV-dependent overlap.[24–26]

Differentiated VIN is found predominately in postmenopausal patients aged 60 years or older. However, there are reports of patients aged 17–39 years developing differentiated VIN; thus, a high index of suspicion is indicated.[25,27,28] Differentiated VIN has a unique pathogenesis characterized by somatic mutations in genes such as *TP53*, resulting in either overexpression or complete loss of the p53 protein, depending on the nature of the mutation.[25]

Historically, differentiated VIN was found in the margins of vulvar squamous cell carcinoma. However, the literature suggests that the detection rate of differentiated VIN has improved over the past 20 years and therefore the incidence of concurrent differentiated VIN and vulvar squamous cell carcinoma is decreasing.[25,29–31] In 2020, Day et al[32] reported that of 120 patients reviewed, an solitary differentiated VIN lesions were identified in 34% of cases; this is compared with a prior study in 2000 in which a staggering 95% of cases had concurrent differentiated VIN and vulvar squamous cell carcinoma.33 Finally, an unclear subset of patients has comorbid HPV-associated HSIL and HPV-independent differentiated VIN from lichen sclerosus, thereby having two pathways to vulvar squamous cell carcinoma.[34]

CLINICAL PRESENTATION AND DIAGNOSIS

For all forms of vulvar precancer, the most common symptom is pruritus, but approximately 40% of patients are asymptomatic and lesions are found on routine examination.[35] Variable morphology on examination makes diagnosis challenging, and a high clinical index of suspicion is warranted.

Human Papillomavirus–Associated High-Grade Squamous Intraepithelial Lesions

Patients who report symptoms describe vulvar pain, itching, burning, or dyspareunia or present with a lesion of concern. High-grade squamous intraepithelial lesions can appear flesh colored, white, red, or pigmented. Lesions can be flat, raised, or warty in appearance. High-grade squamous intraepithelial lesions can present as a single lesion or multifocal. Low-grade squamous intraepithelial lesions and HSILs can occur synchronously[13,36–39] (Figs. 1–3).

Human Papillomavirus–Independent Lesions

Differentiated VIN and its morphologic variants, differentiated exophytic vulvar intraepithelial lesion,

© 2025 by the American College of Obstetricians & Gynecologists. Published by Wolters Kluwer Health, Inc. Unauthorized reproduction of this article is prohibited.



Fig. 1. Perianal low-grade squamous intraepithelial lesions.

Welch. Vulvar Precancerous Squamous Lesions. Obstet Gynecol 2026.

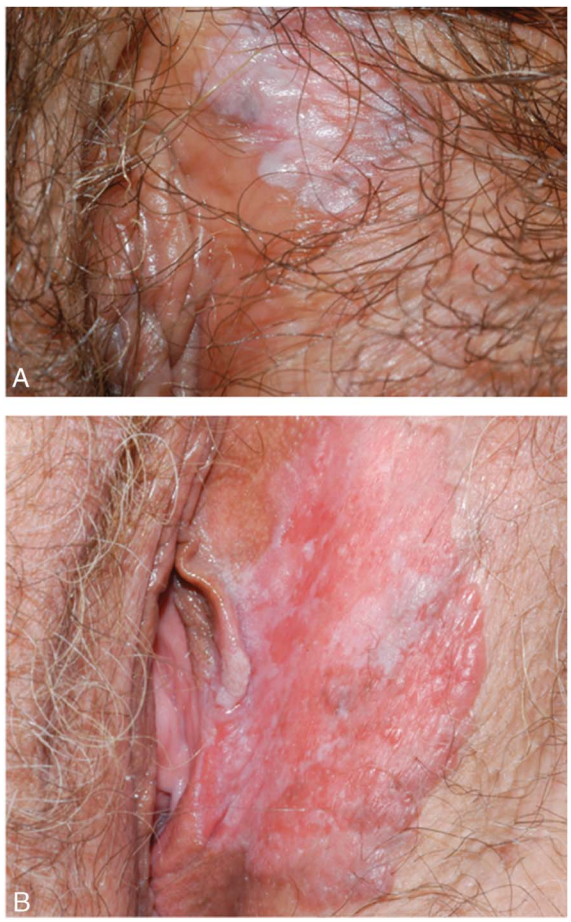

Fig. 2. Multiple presentations of high-grade squamous intraepithelial lesions. Raised white confluent lesion (**A**) and large, single erythematous lesion with raised border (**B**).

Welch. Vulvar Precancerous Squamous Lesions. Obstet Gynecol 2026.

vulvar acanthosis with altered differentiated, and vulvar aberrant maturation, usually arise in the background of lichen sclerosus. These lesions can present in a unifocal or multifocal location. Areas of concern can be raised, thickened, eroded, or ulcerated. As with HSIL, they can have different features



Fig. 3. Multifocal high-grade squamous intraepithelial lesions.

Welch. Vulvar Precancerous Squamous Lesions. Obstet Gynecol 2026.

© 2025 by the American College of Obstetricians & Gynecologists. Published by Wolters Kluwer Health, Inc. Unauthorized reproduction of this article is prohibited.

on the same vulva. Patients with a long history of difficulty controlling lichen sclerosus symptoms, often with secondary lichen simplex chronicus, are at a higher risk of developing cancer than the population that is well controlled. Special attention should be paid to areas of the vulva that do not respond to treatment with topical corticosteroids. Human papillomavirus–independent lesions can be subtle (Figs. 4–6).[13,36–38]

Colposcopy

Colposcopy is a diagnostic procedure used to identify precancerous and cancerous lesions of the vulva, vagina, cervix, and anus.[40] When there is a suspicion for HPV-associated high grade vulvar lesions, 3–5% acetic acid is applied to the vulva and left in place for several minutes. Magnification is then used to closely examine the vulva. Abnormal cells such as dysplastic cells or those infected with HPV appear white after the application of acetic acid, a phenomenon known as the acetowhite change.[41] For HPV-independent lesions, acetic acid is not applied, but illuminated magnification is likewise used.

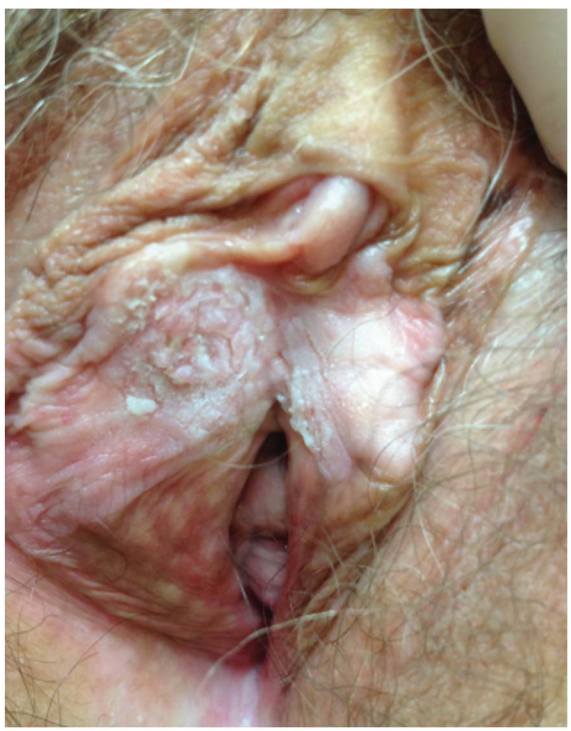

Fig. 4. Human papillomavirus–independent differentiated VIN.

Welch. Vulvar Precancerous Squamous Lesions. Obstet Gynecol 2026.

VULVAR BIOPSY, HISTOPATHOLOGY, AND IMMUNOHISTOCHEMISTRY

Histologic examination is essential for the diagnosis of HSIL or differentiated VIN. The primary clinical scenarios in which biopsy is indicated are when there is concern for precancer and malignancy, as well as treatment failure or uncertain diagnosis. The art of determining when a biopsy is necessary is often a clinical conundrum; shared decision making with patients can help strike a balance.

Lesions that are bleeding, ulcerated, or thickened or have changed in size or morphology should be strongly considered for tissue sampling. A low threshold for biopsy should be used in patients with immunocompromise.

Biopsies should be performed in the thickest area of a lesion when there is concern for precancer or malignancy. For office biopsy, local anesthesia should always be instilled. If multiple biopsies or multizonal evaluation is indicated, further anesthetic options may be considered with the patient. The patient should be consented and verified per health system policy. If a punch biopsy is used, most lesions can be appropriately sampled with a 4-mm punch tool; clinicians should consider sampling at least half depth to full depth of the hilt and be mindful of crush injury to the specimen with tissue removal. A shave or excisional biopsy is also an excellent way to achieve tissue sampling in the unique architecture of the vulva. However, with a concern for cancer, a deeper biopsy is indicated. Multiple biopsies may also be indicated. When possible, biopsies directly on the midline of the vulva should be avoided to facilitate better healing.[42] Lastly, we recommend photo documentation. Clinical photos are invaluable to identify exact biopsy location and to monitor vulvar changes over time and response to treatment. They are also helpful in collaborating with colleagues in a shared practice and in consultation with subspecialists such as pathologists. Written consent for photography is recommended.

In general, HPV-associated lesion descriptions can include grading such as VIN 1, 2, or 3; HSIL; or a broader description such as koilocytosis, cytologic atypia, and increased mitotic figures. Immunohistochemistry is crucial to diagnosis; p16-positive and p53 wild-type staining supports HPV-associated lesions.[38,43,44]

Human papillomavirus–independent lesions usually arise in background inflammation. Descriptions may include differentiated VIN, differentiated exophytic vulvar intraepithelial lesions, vulvar acanthosis with altered differentiated, and vulvar aberrant

© 2025 by the American College of Obstetricians & Gynecologists. Published by Wolters Kluwer Health, Inc. Unauthorized reproduction of this article is prohibited.

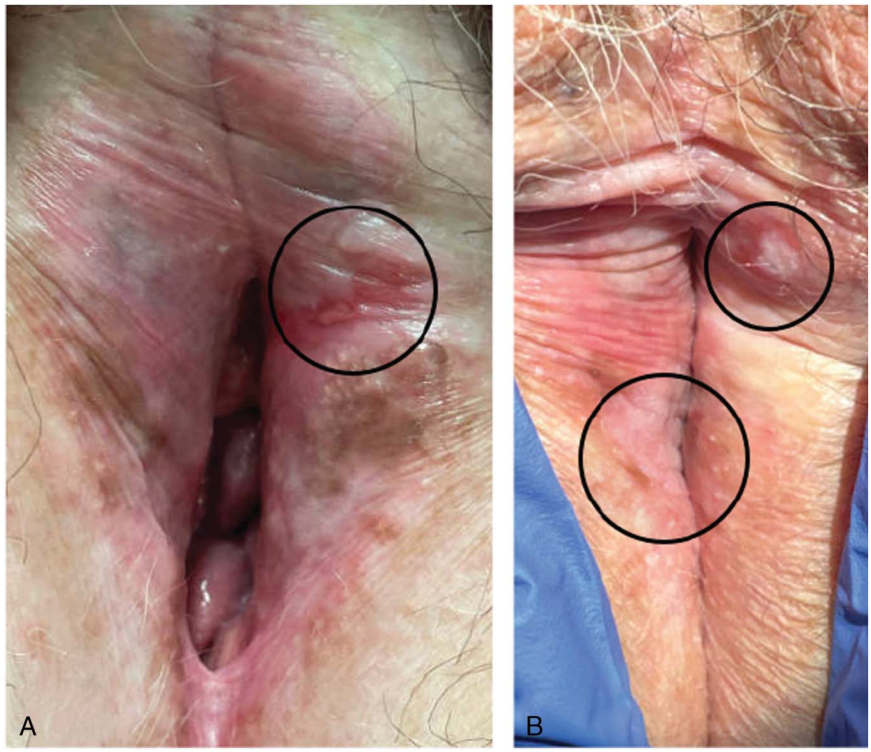

Fig. 5. Human papillomavirus–independent differentiated vulvar intraepithelial neoplasia (VIN) with background vulvar lichen sclerosus. *Circles* denote differentiated VIN. **A.** Vulva with lichen sclerosus and focus of human papillomavirus (HPV)–independent differentiated VIN circled. Note the eroded appearance. **B.** Vulva with lichen sclerosus, with multiple HPV-independent differentiated VINs circled. Note the thickened tissue.

Welch. Vulvar Precancerous Squamous Lesions. Obstet Gynecol 2026.

maturation or broader description of basal cell atypia and premature keratinization (Table 2). Lichen sclerosus does not require biopsy for diagnosis but may be found in the background of differentiated VIN. Aberrant p53 expression and p16-negative staining can help delineate HPV-independent lesions. Because of the complexity of diagnosis, pathology conferences are often necessary for consensus.[25,38,43,45,46]

Determination of whether lesions are HPV associated or HPV independent is vital to patient care in



Fig. 6. Human papillomavirus (HPV)–independent differentiated vulvar intraepithelial neoplasia (VIN), arising in a background of vulvar lichen sclerosus, where biopsy should occur. Same patient before (**A**) and after (**B**) four biopsies made hemostatic with silver nitrate, all with HPV-independent differentiated VIN.

Welch. Vulvar Precancerous Squamous Lesions. Obstet Gynecol 2026.

© 2025 by the American College of Obstetricians & Gynecologists. Published by Wolters Kluwer Health, Inc. Unauthorized reproduction of this article is prohibited.

Table 2. Vulvar Precancers*

HPV Associated	HPV Independent
LSIL or HSIL, VIN 1, VIN 2 or 3	Often associated with lichen sclerosus
Most common	Less common
Younger patient	Older patient
p16 block staining	p16-negative staining
p53 wild-type staining	Aberrant p53 expression
Morphologic variants	
	dVIN
	DEVIL
	Vulvar acanthosis with altered differentiated
	Vulvar aberrant maturation (precursor lesion)
Prognosis	
Spontaneous regression possible (VIN 1 or LSIL)	No spontaneous regression
Slower rate of progression to invasive cancer	Faster rate of progression to invasive cancer
Longer time to invasive cancer	Shorter time to invasive cancer

HPV, human papillomavirus; LSIL, low-grade squamous intraepithelial lesion; HSIL, high-grade squamous intraepithelial lesion; VIN, vulvar intraepithelial neoplasia; dVIN, differentiated vulvar intraepithelial neoplasia; DEVIL, differentiated exophytic vulvar intraepithelial lesion.

* Adapted from 2020 WHO classification of female genital tumors.[10]

that it can inform prognosis and treatment. When biopsy reports are not straightforward, we encourage the clinician to communicate with the pathologist. Further interrogation of the tissue specimen may be warranted to arrive at a diagnosis, or more tissue may be required.

TREATMENT

Human Papillomavirus–Dependent Lesions

Low-Grade Squamous Intraepithelial Lesion (Condyloma Acuminatum) Treatment

Low-grade intraepithelial lesions (condyloma acuminatum) are not precancerous lesions and therefore do not need to be treated unless symptomatic. Many patients can clear these lesions without intervention.

Topical Treatments

When treatment is indicated, topical medications, whether patient applied (imiquimod) or applied in the office (trichloroacetic acid), can be considered.

Surgical Treatments

Procedures such as office cryotherapy, surgical laser ablation, or excision can be offered.[6] For LSILs that do not respond to treatment, a biopsy or evaluation for an underlying immunosuppression should be considered.

High-Grade Squamous Intraepithelial Lesion Treatment

For the treatment of HSIL, the therapeutic goal is to eliminate neoplasia, to preserve vulvar function and appearance, and to reduce cancer risk.[4] Treatment options categories are similar to treatment for LSIL and include topical and surgical treatment.

Surgical Treatment

There are several considerations to the mode of surgical intervention. Surgical excision is preferred if there is concern for invasion. A goal of at least 0.5-mm margins with tissue sparing of vulvar anatomy is generally accepted. When negative margins are achieved, the chance of recurrence is lower than with positive margins. Ablative therapy with a carbon dioxide (CO_2) laser is the preferred treatment for multifocal disease, particularly in the non–hair-bearing areas; however, CO_2 laser is acceptable for a single lesion. The advantages of laser ablation are often the sparing of tissue and less morbidity. There is some debate about a higher rate of recurrence with a CO_2 laser; however, because it is often used in multifocal disease that has a higher rate of recurrence overall, the data are not clear.[4]

Topical Treatments

Topical imiquimod 5% cream and compounded cidofovir 1% cream or ointment demonstrated similar complete response rates of approximately 45% at 6 months, with most adverse events being local and manageable. Notably, cidofovir may be associated with fewer systemic side effects such as fatigue and headache compared with imiquimod, although both agents have similar discontinuation rates and overall tolerability profiles.[47,48]

Topical imiquimod 5% cream, although not approved by the U.S. Food and Drug Administration for this indication, has demonstrated efficacy in randomized controlled trials. Published regimens involve application three times weekly for 12–24 weeks (generally about 16 weeks), with colposcopic assessment follow-up. Residual lesions after medical therapy require surgical management. Imiquimod may be less effective in patients with immunocompromise, and local side effects such as erythema and pain may limit its use. Imiquimod may also be considered for lesions on or near the clitoris or anus.[4]

One randomized phase 3 noninferiority trial included 98 patients with vulvar HSILs. Most patients had focal disease. They completed treatment with imiquimod 5% cream three times weekly for up to 24 weeks. This study showed that imiquimod treatment was noninferior to excision or ablation for treatment.

© 2025 by the American College of Obstetricians & Gynecologists. Published by Wolters Kluwer Health, Inc. Unauthorized reproduction of this article is prohibited.

Clinical response was noted 80% of the time with imiquimod and 79% of the time with surgery. Adverse events in the imiquimod group included pain and pruritus. In contrast, adverse events in the excision group included intense pain. The overall rate of adverse events was also noninferior.[49]

Human Papillomavirus–Independent Lesions

Surgical excision is also the preferred treatment for differentiated VIN and morphologic variants secondary to the higher risk of identifying invasion.[4,32] Although current National Comprehensive Cancer Network guidelines support microscopic Mohs surgery for basal cell carcinoma, dermatofibrosarcoma protuberans, and some penile squamous cell carcinomas, they do not recommend microscopic Mohs surgery for vulvar squamous cell carcinoma. However, Shwe et al[50] suggest that microscopic Mohs surgery is effective for select early-stage vulvar squamous cell carcinoma in conjunction with interdisciplinary management.[51]

PROGNOSIS, RECURRENCE, AND SURVEILLANCE

Overall prognosis varies significantly on individual risk factors, including but not limited to immune status and multizonal disease, but in general, treated HSIL has a rate of progression to vulvar squamous cell carcinoma of 2–5%. Patient groups with a higher risk for progression include those with multifocal disease, individuals with large disease burden on initial clinical presentation, and those who have a history of vulvar squamous cell carcinoma or VIN.

Patients with HPV-independent lesions carry a high-risk of progression to vulvar squamous cell carcinoma, possibly up to 50%, and a worse prognosis than their counterparts with HSIL. Furthermore, the time from the initial diagnosis of an HPV-independent lesion to vulvar squamous cell carcinoma is shorter than for HSIL. Generally, 3–5% of patients with vulvar lichen sclerosus develop vulvar squamous cell carcinoma; this risk seems to be mitigated with topical corticosteroids maintenance regimens.[25,29,52]

For all patients diagnosed with VIN, lifelong surveillance with examination is recommended.[4] Follow-up should be individualized and patient centered. After initial treatment of VIN, with complete clearance of disease, it is reasonable to perform surveillance examination every 6 months for at least 2 years and then annually if no recurrence is identified.[4] However, many patients benefit from more frequent visits of every 3–4 months early in their course or prolonged twice-yearly surveillance, given risk of recurrence. Wallbillich et al[53] found that the median time to recurrence for HSIL was about 18 months; however, a quarter of patients had late recurrence, with a wide variation of 44–196 months. Furthermore, there is a paucity of data, but it is reasonable to suggest that those with two pathways to vulvar squamous cell carcinoma also have a higher risk of progression to vulvar squamous cell carcinoma and should have surveillance tailored to this risk.[2]

At surveillance visits, patients with HSIL should be interviewed about new vulvar signs or symptoms. If appropriate, counseling about modifiable risk factors such as tobacco use should take place.

Evaluation of multizonal disease should be considered. The American College of Obstetricians & Gynecologists, the ASCCP, the Society of Gynecologic Oncology, and the U.S. Preventive Services Task Force concur on cervical cancer screening recommendations. Patients who have a history of vulvar squamous cell carcinoma or HSIL should be managed outside of usual cervical cancer screening algorithms, given the high risk for HPV-associated lesions.[54] In alignment with ASCCP and International Anal Neoplasia Society recommendations, when available, anal cancer screening should be offered within 1 year of diagnosis of HSIL of the vulva.[55] Furthermore, in patients aged 45 years or older with a history of cervical or vaginal HSIL or cancer, extensive perianal condyloma that is persistent (more than 1 year), cervical HPV16, or autoimmune conditions could be considered for anal cytology screening with shared decision making, provided there is adequate capacity to perform diagnostic high-resolution anoscopy.[55]

In patients with a history of HPV-independent lesions, a similar cadence of visits is reasonable. Patients can be interviewed about symptom management of vulvar lichen sclerosus, topical corticosteroid use, and concern for new lesions. Colposcopy without acetic acid should be performed (with acetic acid if comorbid HSIL history) to detect early suspicious lesions. Management of vulvar lichen sclerosus should include a maintenance regimen of topical corticosteroids.[56,57]

We suggest a discussion with the patient about their care team to ensure that while in surveillance, routine health maintenance and other gynecologic care are ongoing. Furthermore, these conditions often have implications on sexual health. It is important to address goals and sexual health challenges with patients who are undergoing diagnosis, treatment, and surveillance. When possible, referrals to sexual health services can be invaluable.[58,59]

© 2025 by the American College of Obstetricians & Gynecologists. Published by Wolters Kluwer Health, Inc. Unauthorized reproduction of this article is prohibited.

PREVENTION

Human Papillomavirus–Associated Lesions

There is a strong association between tobacco use and HPV-associated LSIL and HSIL. Smoking cessation is vital to helping clear HPV-associated disease. Human papillomavirus vaccination is critical in preventing HPV progression. The current vaccine protects against HPV genotypes 6, 11, 16, 18, 31, 33, 45, 52, and 58. Adjuvant vaccination in patients with HSIL changes of the cervix may prevent recurrence of disease.[4,60] Furthermore, Seebauer et al[17] provide support to engage in broader vaccination strategies. A global retrospective study using electronic health records found that individuals vaccinated against HPV (aged 8 years or older) had significantly lower all-cause mortality–about 50% lower–over 8- and 20-year periods compared with unvaccinated individuals. The study suggests that HPV vaccination may offer broader protective effects beyond cervical cancer, potentially reducing the risk of cancers in the head and neck, gastrointestinal, anogenital, neuronal, and especially hematologic systems. However, long-term data are still limited.

Supplementing with active hexose correlated compound, a mushroom extract, is a promising additional option to offer patients. Reports to date have focused on cervical HPV. Taking active hexose correlated compound (3 g daily) was effective in helping the immune system clear persistent HPV infections and was well tolerated with no significant side effects. Continued supplementation beyond the first negative HPV result may be necessary for lasting results.[61]

Human Papillomavirus–Independent Lesions

Effective management of underlying vulvar lichen sclerosus is key in prevention. Maintenance with topical corticosteroids is encouraged. New data support treating patients with long-term topical corticosteroids after their treatment for HPV-independent vulvar squamous cell carcinoma to decrease their chance of recurrence.[56,57]

CONCLUSION

High-grade squamous intraepithelial lesions and differentiated VIN represent critical premalignant conditions of the vulva, with implications that vary widely by subtype. Timely recognition, appropriate classification, and a tailored therapeutic approach are essential to reduce the risk of invasive disease and to preserve quality of life. Preventive strategies, particularly HPV vaccination and management of vulvar lichen sclerosus, play a central role in reducing the burden of VIN. Suggested future directions and areas of study include a better understanding of underlying host immune responses in both pathways. Integration of genomics and molecular profiling to guide treatment may be beneficial. A hot topic is surgical management and vulvar tissue conservation. Ongoing research is exploring the implications of positive surgical margins in differentiated VIN.[53] Continued research is needed to refine diagnostic tools and to develop more targeted, less invasive therapies to arrive at better outcomes for our patients.

REFERENCES

1. Mammas IN, Sourvinos G, Spandidos DA. The paediatric story of human papillomavirus (review). Oncol Lett 2014;8:502–6. doi: 10.3892/ol.2014.2226
2. Eva L, Sadler L, Thompson JM, Sahota S, Fong KL, Jones RW, et al. HPV-independent and HPV-associated vulvar squamous cell carcinoma: two different cancers. Int J Gynecol Cancer 2022;32:1108–14. doi: 10.1136/ijgc-2022-003616
3. Mousavi SE, Ghasemi H, Najafi M, Yekta Z, Nejadghaderi SA. Incidence trends of vulvar cancer in the United States: a 20-year population-based study. Cancer Rep (Hoboken) 2024;7:e2120. doi: 10.1002/cnr2.2120
4. Management of vulvar intraepithelial neoplasia. Committee Opinion No. 675 [published erratum appears in Obstet Gynecol 2017;129:209]. American College of Obstetricians and Gynecologists. Obstet Gynecol 2016;128:e178–82. doi: 10.1097/AOG.0000000000001713
5. Malik S. Nomenclature of vulvar intraepithelial lesions. J Colposcopy Lower Genital Tract Pathol 2024;2:43–4. doi: 10.4103/jclgtp.Jclgtp_12_24
6. New nomenclature for vulvar disease. Am J Obstet Gynecol 1976;124:325–6.
7. Wilkinson E, Kneale B, Lynch P. Report of the ISSVD Terminology Committee. J Reprod Med Obstetrician Gynecologist 1986;31:973–4.
8. Darragh TM, Colgan TJ, Cox JT, Heller DS, Henry MR, Luff RD, et al. The lower anogenital squamous terminology standardization project for HPV-associated lesions: background and consensus recommendations from the College of American Pathologists and the American Society for Colposcopy and Cervical Pathology. Arch Pathol Lab Med 2012;136:1266–97. doi: 10.5858/arpa.LGT200570
9. Bornstein J, Bogliatto F, Haefner HK, Stockdale CK, Preti M, Bohl TG, et al. The 2015 International Society for the Study of Vulvovaginal Disease (ISSVD) terminology of vulvar squamous intraepithelial lesions. J Low Genit Tract Dis 2016;20:11–4. doi: 10.1097/LGT.0000000000000169
10. Höhn AK, Brambs CE, Hiller GGR, May D, Schmoeckel E, Horn LC. 2020 WHO classification of female genital tumors. Geburtshilfe Frauenheilkd 2021;81:1145–53. doi: 10.1055/a-1545-4279
11. Bertoli HK, Thomsen LT, Iftner T, Dehlendorff C, Kjær SK. Risk of vulvar, vaginal and anal high-grade intraepithelial neoplasia and cancer according to cervical human papillomavirus (HPV) status: a population-based prospective cohort study. Gynecol Oncol 2020;157:456–62. doi: 10.1016/j.ygyno.2020.01.030
12. Yim EK, Park JS. The role of HPV E6 and E7 oncoproteins in HPV-associated cervical carcinogenesis. Cancer Res Treat 2005;37:319–24. doi: 10.4143/crt.2005.37.6.319

© 2025 by the American College of Obstetricians & Gynecologists. Published by Wolters Kluwer Health, Inc. Unauthorized reproduction of this article is prohibited.

13. Preti M, Scurry J, Marchitelli CE, Micheletti L. Vulvar intraepithelial neoplasia. Best Pract Res Clin Obstet Gynaecol 2014; 28:1051–62. doi: 10.1016/j.bpobgyn.2014.07.010

14. Jones RW, Rowan DM, Stewart AW. Vulvar intraepithelial neoplasia: aspects of the natural history and outcome in 405 women. Obstet Gynecol 2005;106:1319–26. doi: 10.1097/01.AOG.0000187301.76283.7f

15. Zhang J, Liu G, Cui X, Yu H, Wang D. Human papillomavirus genotypes and the risk factors associated with multicentric intraepithelial lesions of the lower genital tract: a retrospective study. BMC Infect Dis 2021;21:554. doi: 10.1186/s12879-021-06234-0

16. Hui Y, Manna P, Ou JJ, Kerley S, Zhang C, Sung CJ, et al. High-risk human papillomavirus infection involving multiple anatomic sites of the female lower genital tract: a multiplex real-time polymerase chain reaction-based study. Hum Pathol 2015;46:1376–81. doi: 10.1016/j.humpath.2015.05.022

17. Seebauer C, Faluogy M, Sieg P, Olbrich H, Ludwig R. HPV vaccination and malignancy risks beyond cervical cancer: a retrospective global cohort study. Pharmacol Res 2025;218: 107851. doi: 10.1016/j.phrs.2025.107851

18. Hanft W, Stankiewicz Karita H, Khorsandi N, Vohra P, Plotzker R. Sexually transmitted human papillomavirus and related sequelae. Clin Microbiol Rev 2025;38:e0008523. doi: 10.1128/cmr.00085-23

19. Albuquerque A, Godfrey MAL, Cappello C, Pesola F, Bowring J, Cuming T, et al. Multizonal anogenital neoplasia in women: a cohort analysis. BMC Cancer 2021;21:232. doi: 10.1186/s12885-021-07949-8

20. Clifford GM, Georges D, Shiels MS, Engels EA, Albuquerque A, Poynten IM, et al. A meta-analysis of anal cancer incidence by risk group: toward a unified anal cancer risk scale. Int J Cancer 2021;148:38–47. doi: 10.1002/ijc.33185

21. Gupta S, Ahuja S, Kalwaniya DS, Shamsunder S, Solanki S. Vulval premalignant lesions: a review article. Obstet Gynecol Sci 2024;67:169–85. doi: 10.5468/ogs.23274

22. Lebreton M, Carton I, Brousse S, Lavoué V, Body G, Levêque J, et al. Vulvar intraepithelial neoplasia: classification, epidemiology, diagnosis, and management. J Gynecol Obstet Hum Reprod 2020;49:101801. doi: 10.1016/j.jogoh.2020.101801

23. De Luca DA, Papara C, Vorobyev A, Staiger H, Bieber K, Thaçi D, et al. Lichen sclerosus: the 2023 update. Front Med (Lausanne) 2023;10:1106318. doi: 10.3389/fmed.2023.1106318

24. Lin A, Day T, Ius Y, Scurry J. Anogenital high-grade squamous intraepithelial lesion comorbid with vulvar lichen sclerosus and lichen planus. J Low Genit Tract Dis 2020;24:311–6. doi: 10.1097/LGT.0000000000000540

25. Heller DS, Day T, Allbritton JI, Scurry J, Radici G, Welch K, et al. Diagnostic criteria for differentiated vulvar intraepithelial neoplasia and vulvar aberrant maturation. J Low Genit Tract Dis 2021;25:57–70. doi: 10.1097/LGT.0000000000000572

26. Day T, Moore S, Bohl TG, Scurry J. Comorbid vulvar lichen planus and lichen sclerosus. J Low Genit Tract Dis 2017;21: 204–8. doi: 10.1097/LGT.0000000000000307

27. Regauer S. Residual anogenital lichen sclerosus after cancer surgery has a high risk for recurrence: a clinicopathological study of 75 women. Gynecol Oncol 2011;123:289–94. doi: 10.1016/j.ygyno.2011.07.010

28. Al-Ghamdi A, Freedman D, Miller D, Poh C, Rosin M, Zhang L, et al. Vulvar squamous cell carcinoma in young women: a clinicopathologic study of 21 cases. Gynecol Oncol 2002; 84:94–101. doi: 10.1006/gyno.2001.6466

29. Eva LJ, Sadler L, Fong KL, Sahota S, Jones RW, Bigby SM. Trends in HPV-dependent and HPV-independent vulvar cancers: the changing face of vulvar squamous cell carcinoma. Gynecol Oncol 2020;157:450–5. doi: 10.1016/j.ygyno.2020.01.029

30. Medeiros F, Nascimento AF, Crum CP. Early vulvar squamous neoplasia: advances in classification, diagnosis, and differential diagnosis. Adv Anat Pathol 2005;12:20–6. doi: 10.1097/01.pqp.0000151268.72556.f3

31. McAlpine JN, Kim SY, Akbari A, Eshragh S, Reuschenbach M, von Knebel Doeberitz M, et al. HPV-independent differentiated vulvar intraepithelial neoplasia (dVIN) is associated with an aggressive clinical course. Int J Gynecol Pathol 2017;36: 507–16. doi: 10.1097/PGP.0000000000000375

32. Day T, Marzol A, Pagano R, Jaaback K, Scurry J. Clinicopathologic diagnosis of differentiated vulvar intraepithelial neoplasia and vulvar aberrant maturation. J Low Genit Tract Dis 2020;24:392–8. doi: 10.1097/LGT.0000000000000569

33. Jin C, Liang S. Differentiated vulvar intraepithelial neoplasia: a brief review of clinicopathologic features. Arch Pathol Lab Med 2019;143:768–71. doi: 10.5858/arpa.2018-0019-RS

34. Janke MJ, DeBlanc J, Kobernik EK, Skala SL, Hiles GL, Kelly R, et al. Comorbid vulvar lichen sclerosus and high-grade squamous intraepithelial lesions: a management conundrum. J Low Genit Tract Dis 2022;26:319–22. doi: 10.1097/LGT.0000000000000690

35. Faber MT, Sand FL, Albieri V, Norrild B, Kjaer SK, Verdoodt F. Prevalence and type distribution of human papillomavirus in squamous cell carcinoma and intraepithelial neoplasia of the vulva. Int J Cancer 2017;141:1161–9. doi: 10.1002/ijc.30821

36. Dockery LE, Soper JT. Vulvar intraepithelial neoplasia: a review of the disease and current management. Obstet Gynecol Surv 2021;76:55–62. doi: 10.1097/OGX.0000000000000857

37. Kesić V, Vieira-Baptista P, Stockdale CK. Early diagnostics of vulvar intraepithelial neoplasia. Cancers (Basel) 2022;14:1822. doi: 10.3390/cancers14071822

38. Reyes MC, Cooper K. An update on vulvar intraepithelial neoplasia: terminology and a practical approach to diagnosis. J Clin Pathol 2014;67:290–4. doi: 10.1136/jclinpath-2013-202117

39. Lai KW, Mercurio MG. Medical and surgical approaches to vulvar intraepithelial neoplasia. Dermatol Ther 2010;23:477–84. doi: 10.1111/j.1529-8019.2010.01351.x

40. Pierce JG Jr., Bright S. Performance of a colposcopic examination, a loop electrosurgical procedure, and cryotherapy of the cervix. Obstet Gynecol Clin North Am 2013;40:731–57. doi: 10.1016/j.ogc.2013.08.008

41. Marina OC, Sanders CK, Mourant JR. Effects of acetic acid on light scattering from cells. J Biomed Opt 2012;17:085002-1. doi: 10.1117/1.JBO.17.8.085002

42. Diagnosis and management of vulvar skin disorders. ACOG Practice Bulletin No. 224. American College of Obstetricians and Gynecologists. Obstet Gynecol 2020;136:e1–14. doi: 10.1097/AOG.0000000000003944

43. Dasgupta S, Ewing-Graham PC, Swagemakers SMA, van der Spek PJ, van Doorn HC, Noordhoek Hegt V, et al. Precursor lesions of vulvar squamous cell carcinoma–histology and biomarkers: a systematic review. Crit Rev Oncol Hematol 2020; 147:102866. doi: 10.1016/j.critrevonc.2020.102866

44. Thuijs NB, van Beurden M, Duin S, Heideman DAM, Berkhof J, Steenbergen RDM, et al. High-grade vulvar intraepithelial neoplasia: comprehensive characterization and long-term vul-

© 2025 by the American College of Obstetricians & Gynecologists. Published by Wolters Kluwer Health, Inc. Unauthorized reproduction of this article is prohibited.

var carcinoma risk. Histopathology. 2024;84:301–14. doi: 10.1111/his.15050

45. Hoang LN, Park KJ, Soslow RA, Murali R. Squamous precursor lesions of the vulva: current classification and diagnostic challenges. Pathology 2016;48:291–302. doi: 10.1016/j.pathol.2016.02.015

46. Schechter SA, Chan MP, Muthusamy S, Skala SL, Wang GY. Interobserver agreement across subspecialties for diagnosis of differentiated vulvar intraepithelial neoplasia and predictive values of 20 histologic features. Arch Pathol Lab Med 2023;147:1431–7. doi: 10.5858/arpa.2022-0088-OA

47. Tristram A, Hurt CN, Madden T, Powell N, Man S, Hibbitts S, et al. Activity, safety, and feasibility of cidofovir and imiquimod for treatment of vulval intraepithelial neoplasia (RT^{3}VIN): a multicentre, open-label, randomised, phase 2 trial. Lancet Oncol 2014;15:1361–8. doi: 10.1016/S1470-2045(14)70456-5

48. Lawrie TA, Nordin A, Chakrabarti M. Medical and surgical treatments for usual-type vulvar intraepithelial neoplasia. JAMA Oncol 2016;2:1647–8. doi: 10.1001/jamaoncol.2016.2430

49. Trutnovsky G, Reich O, Joura EA, Holter M, Ciresa-König A, Widschwendter A, et al. Topical imiquimod versus surgery for vulvar intraepithelial neoplasia: a multicentre, randomised, phase 3, non-inferiority trial. Lancet 2022;399:1790–8. doi.: 10.1016/S0140-6736(22)00469-X

50. Shwe S, Elsensohn AN, Ortiz C, Kraus CN. Mohs micrographic surgery for vulvar malignancies: a systematic review. J Am Acad Dermatol 2022;87:159–62. doi: 10.1016/j.jaad.2021.06.875

51. Nugent ST, Raj LK, Latif NA, Cory L, Tanyi JL, Kovach SJ III, et al. A retrospective case series of Mohs micrographic surgery and interdisciplinary management of female genital skin cancers: local recurrence rates and patient-reported outcomes. J Am Acad Dermatol 2023;89:301–8. doi: 10.1016/j.jaad.2023.02.050

52. Lee A, Bradford J, Fischer G. Long-term management of adult vulvar lichen sclerosus: a prospective cohort study of 507 women. JAMA Dermatol 2015;151:1061–7. doi: 10.1001/jamadermatol.2015.0643

53. Wallbillich JJ, Rhodes HE, Milbourne AM, Munsell MF, Frumovitz M, Brown J, et al. Vulvar intraepithelial neoplasia (VIN 2/3): comparing clinical outcomes and evaluating risk factors for recurrence. Gynecol Oncol 2012;127:312–5. doi: 10.1016/j.ygyno.2012.07.118

54. US Preventive Services Task Force; Curry SJ, Krist AH, Owens DK, Barry MJ, Caughey AB, Davidson KW, et al. Screening for cervical cancer: US Preventive Services Task Force recommendation statement. JAMA 2018;320:674–86. doi: 10.1001/jama.2018.10897

55. Stier EA, Clarke MA, Deshmukh AA, Wentzensen N, Liu Y, Poynten IM, et al. International Anal Neoplasia Society's consensus guidelines for anal cancer screening. Int J Cancer 2024;154:1694–702. doi: 10.1002/ijc.34850

56. Chin S, Scurry J, Bradford J, Lee G, Fischer G. Association of topical corticosteroids with reduced vulvar squamous cell carcinoma recurrence in patients with vulvar lichen sclerosus. JAMA Dermatol 2020;156:813–4. doi: 10.1001/jamadermatol.2020.1074

57. Wijaya M, Lee G, Fischer G, Lee A. Quality of life in vulvar lichen sclerosus patients treated with long-term topical corticosteroids. J Low Genit Tract Dis 2021;25:158–65. doi: 10.1097/LGT.0000000000000599

58. Huffman LB, Hartenbach EM, Carter J, Rash JK, Kushner DM. Maintaining sexual health throughout gynecologic cancer survivorship: a comprehensive review and clinical guide. Gynecol Oncol 2016;140:359–68. doi: 10.1016/j.ygyno.2015.11.010

59. Olesen ML, Seibaek L, Sekse RJT. Impaired sexual health among women treated for vulvar cancer: an integrated review. J Clin Nurs 2023;32:6212–28. doi: 10.1111/jocn.16753

60. Bryan S, Barbara C, Thomas J, Olaitan A. HPV vaccine in the treatment of usual type vulval and vaginal intraepithelial neoplasia: a systematic review. BMC Womens Health 2019;19:3. doi: 10.1186/s12905-018-0707-9

61. Smith JA, Gaikwad AA, Mathew L, Rech B, Faro JP, Lucci JA III, et al. AHCC® supplementation to support immune function to clear persistent human papillomavirus infections. Front Oncol 2022;12:881902. doi: 10.3389/fonc.2022.881902

PEER REVIEW HISTORY

Received August 20, 2025. Received in revised form October 23, 2025. Accepted October 30, 2025. Peer reviews and author correspondence are available at http://links.lww.com/AOG/E458.

© 2025 by the American College of Obstetricians & Gynecologists. Published by Wolters Kluwer Health, Inc. Unauthorized reproduction of this article is prohibited.